

See discussions, stats, and author profiles for this publication at: <https://www.researchgate.net/publication/272993156>

Esthetic Crowns for Primary Teeth: A Review

Article in ANNALS AND ESSENCES OF DENTISTRY · March 2010

DOI: 10.5368/aedj.2010.2.2.87-93.pdf

CITATIONS

15

3 authors, including:



Suzan Sahana
St. Joseph Dental College, Eluru

25 PUBLICATIONS 98 CITATIONS

SEE PROFILE

READS

2,553



Aron Arun Kumar Vasa
Dr. Nandamuri Taraka Rama Rao University of Health Sciences

23 PUBLICATIONS 152 CITATIONS

SEE PROFILE

ESTHETIC CROWNS FOR PRIMARY TEETH: A REVIEW

* Suzan Sahana, ** Aron Arun Kumar Vasa, *** Ravichandra Sekhar

* Sr. Lecturer

** Sr. Lecturer

*** Professor and Head

Department of Pedodontics & Preventive Dentistry, St. Joseph Dental College, Eluru. India

ABSTRACT:

A variety of esthetic restorative materials are available for restoring primary incisors. Each has distinct advantages and disadvantages and the clinical conditions of placement may be a strong determining factor so as to which material is utilized. Full coronal restoration of primary incisors may be indicated for a number of reasons. Crowns available for restoration of primary incisors include those that are directly bonded to the tooth which generally are made up of a resin material, and those crowns that are luted onto the tooth. This paper reviews the published data on restorations of primary anterior teeth and various forms of full coronal restorations for the same.

KEYWORDS: *Esthetic materials, Primary anteriors, Restorations*

INTRODUCTION

Despite the introduction of various novel techniques for restoring carious lesions in the primary incisors, still it is a challenge for the clinician to satisfy the patient effectively. It is becoming a greater concern as more emphasis is being placed on esthetics. Esthetics, by definition, is the science of beauty: that particular detail of an animate or inanimate object that makes it appealing to the eye.¹

In the modern civilized cosmetically conscious world, well contoured and well aligned white teeth set the standard for beauty. Such teeth are not only considered attractive, but are also indicative of nutritional health, self esteem, hygienic pride and economic status.¹ With the growing awareness of the esthetic options available, there is a greater demand for solutions to unsightly problems such as nursing bottle caries, malformed and discolored teeth, hypoplastic defects, tooth fractures and bruxism in children.

Esthetic restoration of primary anterior teeth can be especially challenging due to the small size of the teeth, close proximity of pulp to tooth surface, relatively thin enamel and surface area for bonding, issues related to child behavior and finally cost of the treatment.² Apart from a compromise in esthetics, dental destruction may also lead to development of parafunctional habits like tongue thrusting and speech problems, psychological

problems, reduced masticatory efficiency and loss of vertical dimension of occlusion.³ Hence it is important to restore crowns destroyed by caries to preserve the integrity of primary dentition until its exfoliation and eruption of permanent teeth.

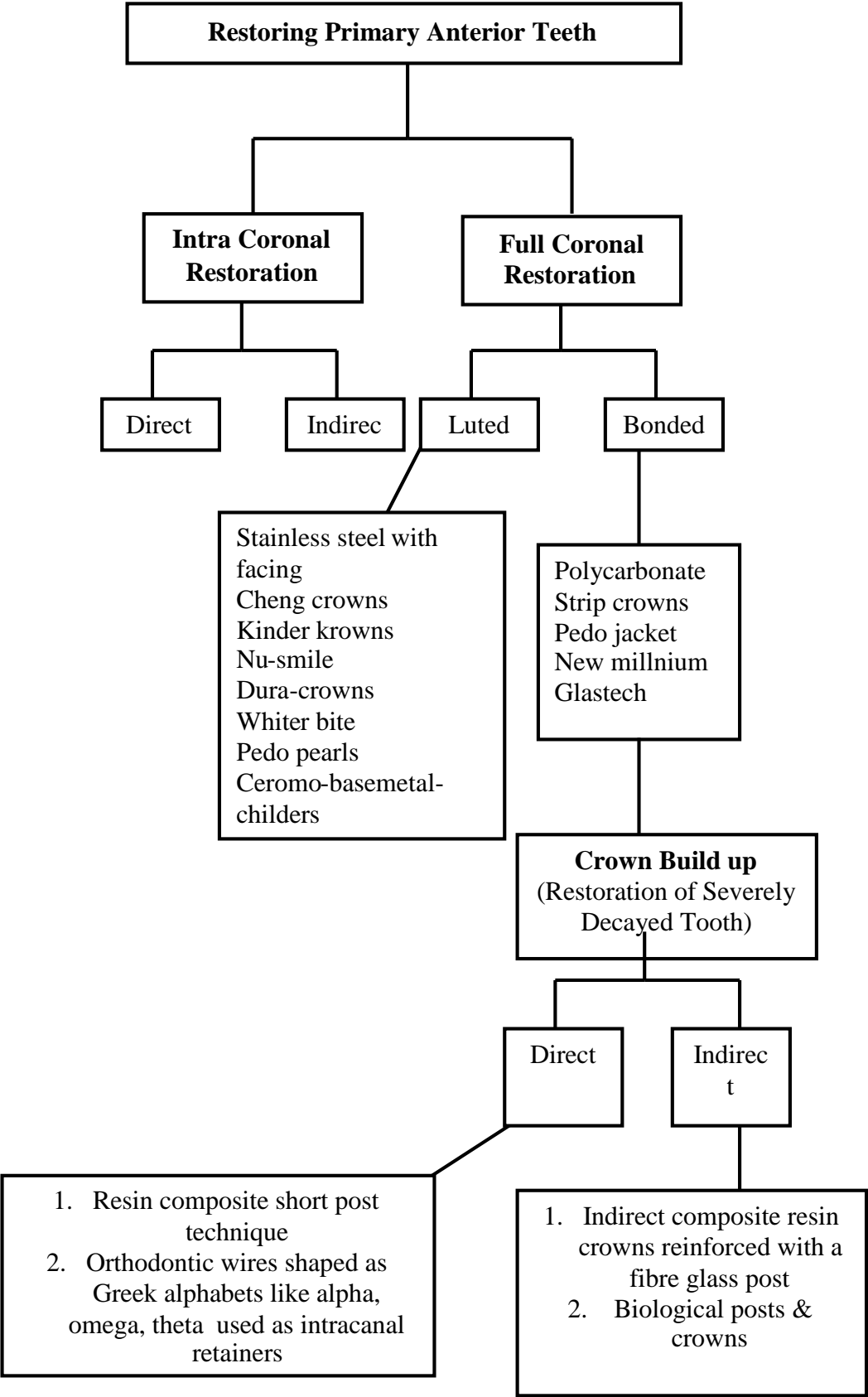
The purpose of this article is to review the various esthetic options available for restoring the primary incisors and enhance the clinician's ability to make the best choice of selection for each individual situation.

Full coronal restorations

Indications for this include:

- Caries present on multiple surface.
- Extensive cervical decalcification
- Anteriors that have received pulp therapy
- Anteriors that have fractured and lost most of the tooth structure
- Anterior teeth with multiple hypoplastic defects or developmental disturbances
- Discolored teeth that are aesthetically unpleasing
- High risk patients where the oral hygiene is poor but caries is minimal.

The child's behavior makes moisture control difficult in placing class III restorations⁴



1. STAINLESS STEEL CROWNS

Stainless steel crowns are considered to be the most durable, economical and reliable for restoring severely carious and fractured primary incisors. They are easy to place, fracture proof, wear resistant and attached firmly to tooth until exfoliation. However there is a compromise in esthetics due to the unsightly silver metallic appearance.⁵

MODIFICATIONS OF STAINLESS STEEL CROWNS

a. *Facial cut out Stainless steel crowns*

This involves placement of composite material in a labial fenestration of SSC. Although there is an improvement in the appearance, the technique is time consuming and metal margins are still visible. Clinicians even face problems to control hemorrhage during application of composite facing.⁵

b. *Veneered Stainless steel crowns*

Here the composite resins and thermoplastics are bonded to the metal. This type of veneered crown was developed to serve as a convenient, durable, reliable, and esthetic solution to the difficult challenge of restoring severely carious primary incisors. Various commercially available veneered SSCs include Cheng crowns, Kinder crowns, Nu-smile and Whiter biter, pedo compu crowns and Dura crowns.⁵

Cheng Crowns

Cheng Crowns made their public debut in 1987.

These are Stainless steel pediatric anterior crowns faced with a high quality composite, mesh-based with a light cured composite. It presents a unique solution for natural-looking Stain-resistant Crowns. It is available for the right and left central and lateral as well as cuspids.

Most crown procedures can be completed in one patient visit and with less patient discomfort.⁶

It is available in short and regular lengths and sizes suitable for centrals, lateral and cuspids. They can undergo heat sterilization without significant effect on their bond strength and color. Disadvantages of all veneered crowns are fracture of veneers during crimping and they are expensive.⁶

It is a Stainless steel crown faced with high quality composite. Manufacturer claims it to be Color stable, plaque resistant and matches pedo-shades. It doesn't cause wear of opposing teeth.

However there are no long term clinical trials to assess the durability of these crowns

It is available in upper and lower – right & left central and lateral with 6 sizes.

Dura crowns

Crowns can be crimped labially and lingually, can be easily trimmed with crown scissors, easily festooned and has got a full-knife edge. Study has shown that these crowns with veneer facings were significantly more retentive than the nonveneered ones when cement and crimping were combined.⁷

Kinder crowns :

Kinder Crowns offer the most natural shades and contour available for the pediatric patient. The great depth and vitality from the lifelike composite reveal a natural smile without the bulky "Chiclet" look of other restorations. They come in 2 aesthetically pleasing shades, Pedo 1 and Pedo 2. Pedo 2 shade is the most natural shade While Pedo 1 shade is for those cases when the bleached white shade is wanted.

Kinder Crowns are designed with IncisaLock™ - the optimal union of state-of-the-art bonding procedures and mechanical retention. By adding mechanical retention and more composite, Kinder Crowns are strong without sacrificing form or function.⁶

PEDO PEARLS™

These are beautiful heavy gauge aluminum crowns coated with FDA food grade powder coating and epoxy-resin. They serve as ultimate permanent crown for primary teeth. Features include:

- Universal anatomy--use on either side
 - Easy to cut and crimp, without chipping or peeling.
 - Composite can be added
- Disadvantages include less durability and the crowns are relatively soft.⁸

BONDED CROWNS

a. **Polycarbonate Crowns:**

These are heat molded acrylic resin used to restore primary anterior teeth. It is esthetic than SSC, easy to trim and can be adjusted with pliers. These crowns do not resist strong abrasive forces thus leading to occasional fracture, hence it is contraindicated in cases of Severe bruxism and deep bite.⁸

b. **Strip crowns :**

These are commonly used Crown forms filled with composite & bonded on the tooth.

The benefits of these crowns include

- Parent/patient pleasing
- Ideal for ankylosed tooth build –ups
- Simple to fit & trim
- Removal is fast & easy
- Easily matches natural dentition
- Leaves smooth shiny surface
- Easy shade control with composite
- Superior esthetic quality
- Ideal for photo cure
- Crystal clear and thin
- Large selection of size
- Easy to repair

However it is technique sensitive, adequate tooth structure is required and any lapses in patient selection, moisture and hemorrhage control, tooth preparation and resin placement can lead to failure.⁹

c. **Pedo jacket**

It is a tooth colored copolyester material which is filled with resin and left on tooth after polymerization instead of being removed. It does not split, stain or crack. Crowns can be easily trimmed with scissors.

Dis-advantage :

- Only one size is available.
- Cannot be trimmed with bur

d. **New millenium**

These crowns are made up of Lab enhanced composite resin material. No long term studies are available regarding these crowns.

e. **Glastech**

Made of Artglass, which is a polymer glass. It gives a natural feel, bondability and kindness associated with composite but the esthetics and longevity of porcelain. It is

Color stable, wear of polymer glass is similar to enamel, kind to opposing dentition and is plaque resistant. The unique filler materials of microglass and silica are proposed to provide greater durability and esthetics than strip crowns.

Restoration of Severely Decayed Tooth

1. Crown build up using resin composite short post technique

Resin composites used directly or indirectly has been an excellent choice for severely carious teeth due to their adhesive bonding and esthetic appearance. The technique involves placement of light cured resin composite in the root canal and crown region in several steps where the cervical

third of root is left unobturated. This eventually forms the superstructure of the post. During next visit, celluloid crowns will be used to build up the teeth.

This procedure reduces operator chairtime and they do not require a layer of opaque material as used in metal posts. The celluloid crown is filled with same material used in fabricating the post, hence it produces a glossy finish thereby minimizing polishing.^[11]

2. Orthodontic wires shaped as Greek alphabets like alpha, omega, theta used as intracanal retainers

The core build-ups are done directly or indirectly over these wires.

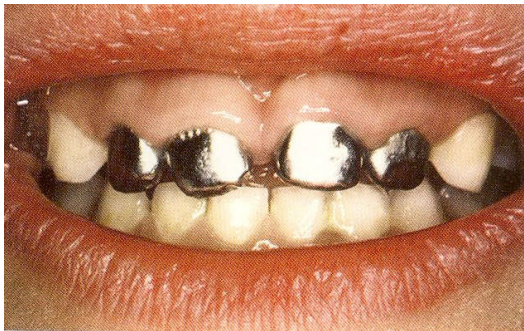Mortada and King(2004) proposed this technique involving the placement of an omega shaped stainless steel wire extension into the entrance of the root canal prior to restoring the crown with an internal compomer core and an external composite restoration. The modified omega loop is an efficient technique for the restoration of the severely damaged anterior teeth. The ease of manipulation and short chair-side time are further advantages of the technique.¹²

3. Indirect composite resin crowns reinforced with a fibre glass post

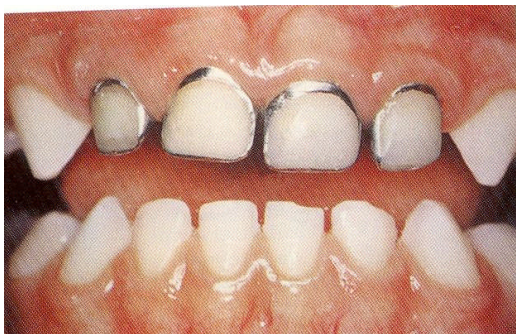
With the introduction of new adhesive systems and restorative materials, a new approach for treating severely mutilated anterior teeth is explained and documented by clinical cases, where fiber core posts are introduced into the root canals of primary incisors for a distance of 2 to 3 mm. It is retained in place by flowable composite, then the coronal part is reconstructed by a strip crown to restore the crown form. A laboratory testing of the fracture load resistance of the restored teeth proved that this technique significantly improved the fracture load resistance of composite celluloid crowns, making it a valuable procedure to consider when the coronal tooth structure is not enough to support and retain a composite celluloid strip crown.¹³

4. Biological posts and crowns

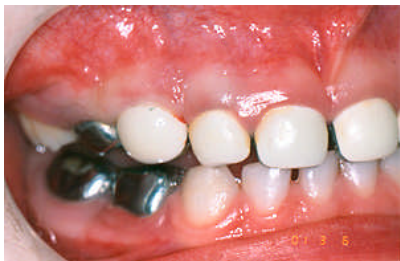Biological restoration was introduced by Santos & Bianchi in 1991. Here, used teeth from the Human Tooth Bank are used as natural posts & crowns. The selected tooth from the tooth bank is reshaped, roots strengthened by retro filling with flowable composites and autoclaved for 30min at 121 degree centigrade and 15 lbs pressure before cementation.



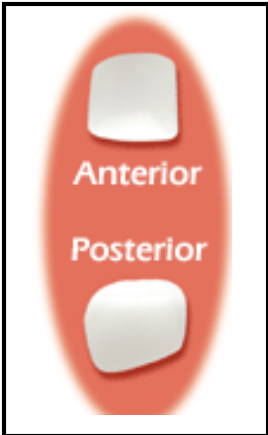
Stainless Steel Crowns



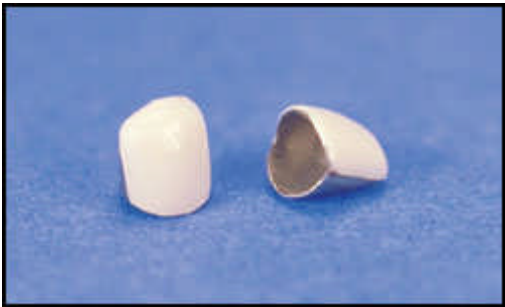Modification of Stainless Steel Crowns



Cheng Crowns



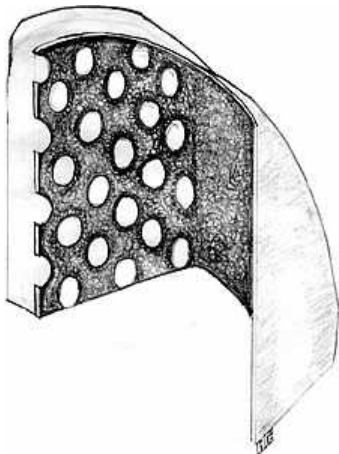
NuSmmile®



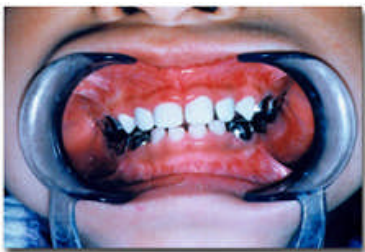Pedo-compu crowns



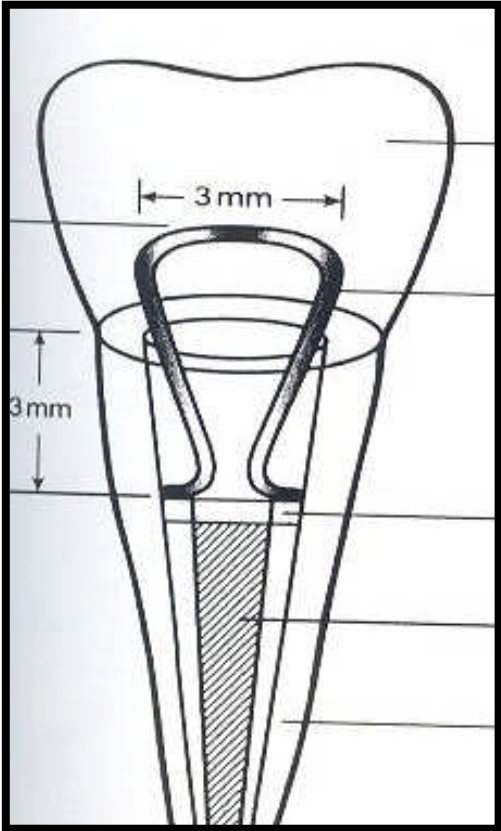
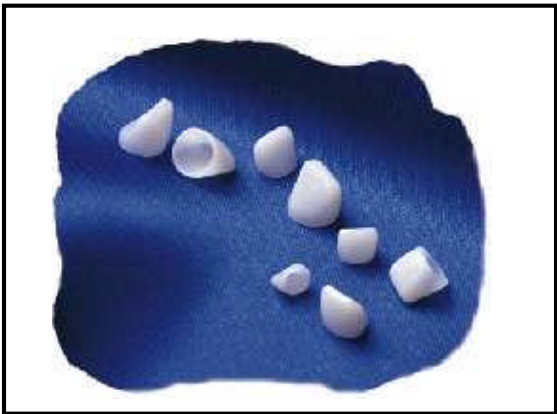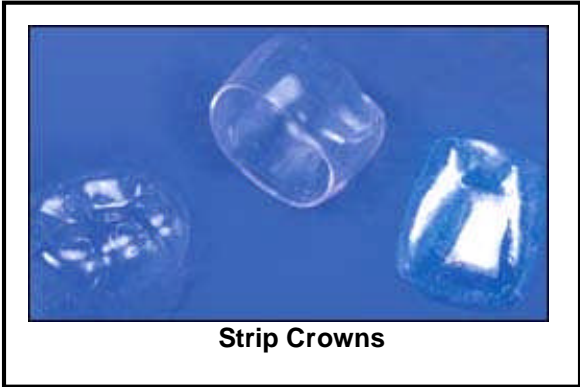Dura Crowns



Kinder Crowns



Pedo Pearls



The natural crowns offer esthetics as well as preserves natural teeth colour. The enamel also has physiologic wear and offer superficial smoothness and cervical adaptation is compatible with those of surrounding teeth. The length of each appointment is reduced because natural teeth are prepared previously. Further more, the technique eliminates laboratory processing and is economical.

Although the technique is simple, it requires professional expertise to prepare and adapt the natural crowns and intracanal posts.

Studies have shown that it is cost effective, clinician friendly, less technique sensitive and esthetic alternative to commercially available restorative materials.

Other factors of concern while using biologic restoration is that Universal protocol of consent, storage and sterilization should be followed in the human tooth bank.

Collected samples should be scaled, polished and freed of soft tissues and periodontal remnants. Pulpas have to be removed and complete biological preparation is to be done.

Teeth are then stored at 4degree centigrade in HBSS with donor identification till the time of its use.¹⁴

CONCLUSION

Many restorative options exist for treating primary anterior teeth. Finally the choice of restorative technique depends upon the operator preferences, esthetic demands by the parents and child's behavior that affect the ultimate outcome of whichever restorative material chosen.

REFERENCES

1. Arens D. The Role of Bleaching in Esthetics. Dent Clin N Am 1989; 33:319-36.
2. Shah PV, Lee JY, Wright JT. Clinical success and parental satisfaction with anterior preveneered primary stainless steel crowns. Pediatr Dent 2004;26:391-5.
3. Usha M, Deepak V, Venkat S, Gargi M. Treatment of severely mutilated incisors: a challenge to the pedodontist. J Indian Soc Pedod Prev Dent 2007;25 Suppl:S34-6.
4. Waggoner WF. Restoring primary anterior teeth:Review.Pediatr Dent 2002;24:511- 6.
5. Lee JK. Restoration of primary anterior teeth: review of the literature. Pediatr Dent 2002;24:506-10.
6. Baker LH, Moon P, Mourino AP. Retention of esthetic veneers on primary stainless steel crowns. ASDC J Dent Child 1996;63:185-9.
7. Guelmann M, Gehring DF, Turner C. Retention of veneered stainless steel crowns on replicated typodont primary incisors: an in vitro study. Pediatr Dent 2003;25:275-8.
8. Yilmaz Y, Guler C. Evaluation of different sterilization and disinfection methods on commercially made preformed crowns. J Indian Soc Pedod Prev Dent 2008;26:162-7.
9. Kupietzky A, Waggoner WF, Galea J. The clinical and radiographic success of bonded resin composite strip crowns for primary incisors. Pediatr Dent 2003;25:577-81.
10. Austinglastech.com [Internet]. Austin, TX: Glastech Inc.; C 2001 [Cited 2010 Feb 11]. Available from: <http://www.austinglastech.com/comp.htm>.
11. Mendes FM, De Benedetto MS, del Conte Zardetto CG, Wanderley MT, Correa MS. Resin composite restoration in primary anterior teeth using short-post technique and strip crowns: a case report. Quintessence Int 2004;35:689-92.
12. Mortada A, King NM. A simplified technique for the restoration of severely mutilated primary anterior teeth. J Clin Pediatr Dent. 2004;28:187-92.
13. Sharaf AA. The application of fiber core posts in restoring badly destroyed primary incisors. J Clin Pediatr Dent. 2002;26:217-24.
14. Mandrolip S. Biologic restoration of primary anterior teeth : A case report . J Indian Soc Pedo Prev Dent 2003;21:95 -7.

Corresponding Author :

Dr. Suzan Sahana MDS

Sr. Lecturer, Department of Pedodontics and Preventive Dentistry,
St. Joseph Dental College, Eluru. India
Pin: 534 003

Email: - drsuzansahana@gmail.com
Ph: +91-98862-31079
Ph: - +91-8812-277634