

See discussions, stats, and author profiles for this publication at: <https://www.researchgate.net/publication/325256953>

# Qualitative Assessment of Reliability of Cone-beam Computed Tomography in evaluating Bone Density at Posterior Mandibular Implant Site

Research in The Journal of Contemporary Dental Practice · May 2018

DOI: 10.5005/jp-journals-10024-2278

CITATIONS

2

READS

235

1 author:



Pankaj Bajaj

PDM Dental College & Research Institute

4 PUBLICATIONS 4 CITATIONS

SEE PROFILE

Some of the authors of this publication are also working on these related projects:



Qualitative Assessment of Reliability of Cone-beam Computed Tomography in evaluating Bone Density at Posterior Mandibular Implant Site [View project](#)



## Qualitative Assessment of Reliability of Cone-beam Computed Tomography in evaluating Bone Density at Posterior Mandibular Implant Site

<sup>1</sup>Kirti Dahiya, <sup>2</sup>Narendra Kumar, <sup>3</sup>Pankaj Bajaj, <sup>4</sup>Avdesh Sharma, <sup>5</sup>Rohan Sikka, <sup>6</sup>Sagar Dahiya

### ABSTRACT

**Introduction:** The success of dental implants depends primarily on the primary implant stability and the bone density so that predictable osseointegration can be achieved. To achieve the desired results, systematic preoperative planning for implant placement is required. The sole aim of the study was to assess the reliability of preoperative bone density of mandibular posterior region for implant placement using computerized tomography-derived bone densities in Hounsfield units (HU).

**Materials and methods:** A total of 200 patients with 352 implant sites between 2014 and 2017 were assessed for the posterior mandibular area using cone-beam computed tomography (CBCT). Evaluation was done by two experienced observers independently.

**Results:** The mean bone density of males was  $690.5 \pm 104.12$  HU and in females, it was  $580.20 \pm 120.2$  HU. Overall, 21% of sites were of low bone density, 39.5% were of intermediate density, and 39.4% were of high density. Receiver operating characteristic (ROC) analysis presented that the CBCT intensity values had a high predictive power for predicting both high-density sites and intermediate-density sites.

**Conclusion:** We can say from our results that, for predicting the bone densities in posterior mandible for determining implant sites, so as to achieve best osseointegration, CBCT values can be reliably used.

**Clinical significance:** It has been proved that bone density and implant stability are dependent on each other and osseointegration is important for the success of treatment. With advancements in dentistry and introduction of CBCT, treatment planning and prediction of appropriate implant sites could be made easy and more predictable. Thus, we can say that CBCT can be considered an alternative diagnostic tool for the bone density evaluation during treatment planning for implant placement.

**Keywords:** Bone density, Cone-beam computed tomography, Implants, Osseointegration.

**How to cite this article:** Dahiya K, Kumar N, Bajaj P, Sharma A, Sikka R, Dahiya S. Qualitative Assessment of Reliability of Cone-beam Computed Tomography in evaluating Bone Density at Posterior Mandibular Implant Site. J Contemp Dent Pract 2018;19(4):426-430.

**Source of support:** Nil

**Conflict of interest:** None

### INTRODUCTION

These days, with advancements in treatment options, rehabilitation using implants has become a popular treatment option among patients. Many factors are associated with implant survival and stability. These factors include both patient-related (such as bone quality and quantity) and nonpatient-related factors (such as implant design and surgical procedure).<sup>1</sup> The success of dental implants depends primarily on the primary implant stability and the bone density so that predictable osseointegration can be achieved.<sup>2,3</sup> To achieve the desired results, a systematic preoperative planning for implant placement is required. To assist in the planning, new techniques are being continuously introduced and checked for their reliability and specificity. One such method of the estimation of bone density gaining interest is the use of CBCT in determining the implant site by evaluating the bone density. Just after the introduction of multislice CT for preoperative

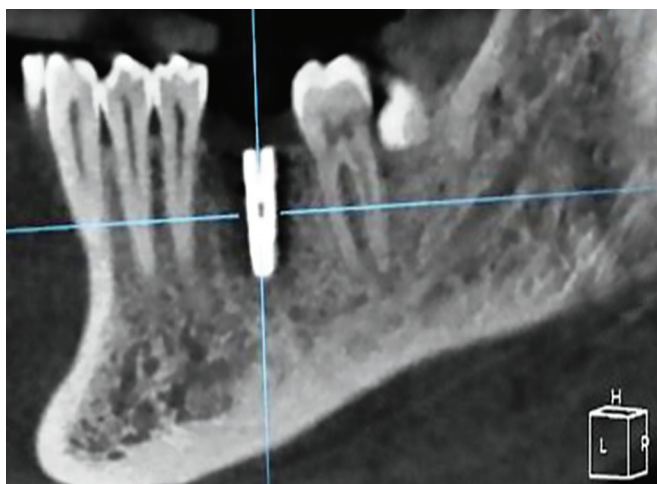
<sup>1,2</sup>Department of Prosthodontics, Institute of Dental Studies & Technologies, Modinagar, Uttar Pradesh, India

<sup>3,5</sup>Department of Prosthodontics, PDM Dental College & Research Institute, Bahadurgarh, Haryana, India

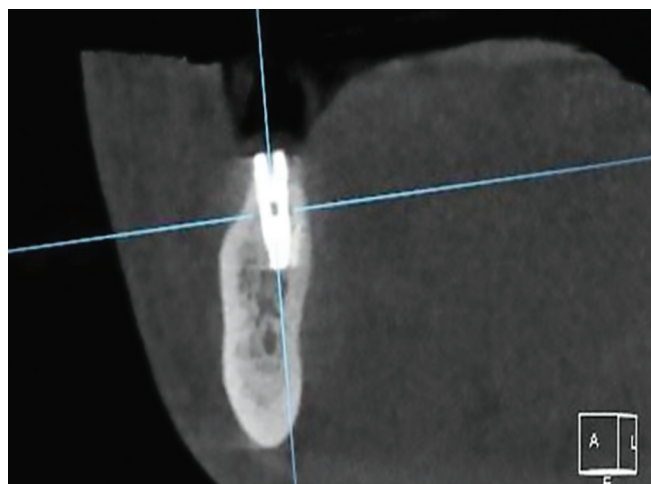
<sup>4</sup>Department of Conservative Dentistry, PDM Dental College & Research Institute, Bahadurgarh, Haryana, India

<sup>6</sup>Department of Orthodontics, Army Dental Corps, Tezpur Assam, India

**Corresponding Author:** Kirti Dahiya, Department of Prosthodontics, Institute of Dental Studies & Technologies Modinagar, Uttar Pradesh, India, Phone: +917417240511, e-mail: Kirti.dahiya87@gmail.com



**Fig. 1:** Low-implant bone density on CBCT

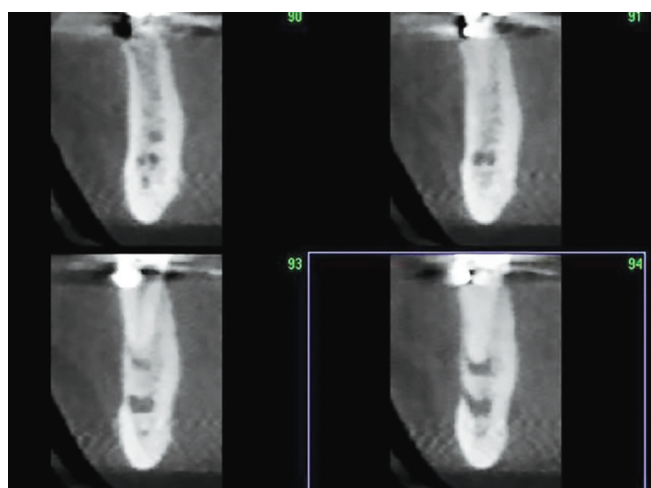


**Fig. 2:** Intermediate-implant bone density on CBCT

evaluation of bone density in HU, various classifications were proposed for standardization. Shortly, CBCT has gained importance, as it is associated with benefits, such as increased patient comfort, lower radiation doses, and lower operating costs compared with conventional CT. It has been reported that CBCT provides submillimeter isotropic voxels allowing accurate measurements, with minimal magnification and distortion (error <0.1 mm), allowing safe dental implant insertion.<sup>4</sup> It has been reviewed that CBCT values are influenced by various other additional factors, such as the kind of device used, imaging parameters, and its positioning. Thus, the present study was aimed to assess the reliability of preoperative bone density of mandibular posterior region for implant placement using CT-derived bone densities in HU.

## MATERIALS AND METHODS

The study was conducted in the Department of Prosthodontics, Institute of Dental Studies & Technologies. Ethical clearance for the study was taken from the concerned Institutional Ethical Committee before the commencement of the study. A total of 200 cases were selected from the archives of the department and included those patients who have undergone CBCT examination for various dental treatments from a time period of approximately 3 years, i.e., from August 2014 to August 2017. The age range of the studied patients was from 25 to 50 years. According to the inclusion criteria, CBCT of only those patients was included who had missing posterior teeth. We excluded those cases which had some pathology in the posterior mandibular area and those in which posterior mandibular areas cannot be assessed clearly. For CBCT imaging, we used KODAK™ 9500 CB three-dimensional (3D) system (Carestream, Rochester, New York, USA) with flat panel detector. The mean bone density was determined in the posterior mandibular area where



**Fig. 3:** High-implant bone density on CBCT

the implant placement was planned. With this method, the measurement of the grayscale image of the CT scan was done, which was used further to measure the bone intensity values HU. Examination for each case was done at a 360° rotation in the occlusal position. For the evaluation purpose, based on bone density, the classification used was: Low density (if marrow spaces filled most of the evaluated bone site: Fig. 1), intermediate density (if bony trabeculae filled half of the evaluated bone site: Fig. 2), and high density (if bony trabeculae filled most of the evaluated bone site: Fig. 3). Two separate observers were selected with more than 5 years of experience to evaluate the selected sample of CBCT images for implant placement. A set of two readings were recorded from each observer with a gap of 1 month in between the two evaluations.

## STATISTICAL ANALYSIS AND RESULTS

The two sets of readings obtained from each observer were recorded and tabulated and sent for statistical

**Table 1:** Study group characteristics

Patient characteristic	Mean
Total sample (n)	200
Gender	
Male	96
Female	104
Age (years)	42.5
Total implant sites studied	352
Premolar area	72
Molar area	280

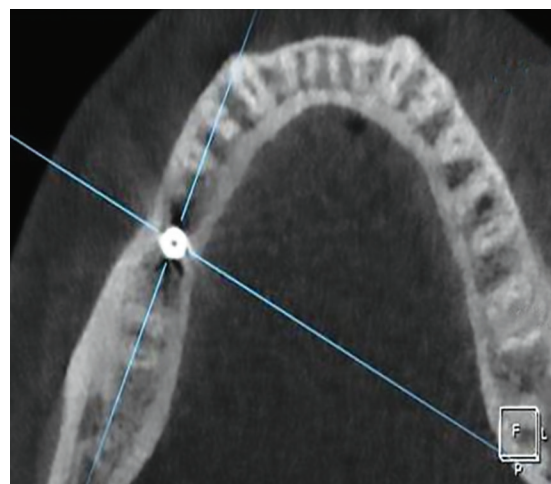
**Table 2:** Overall recorded mean values given by both the observers in two consecutive evaluations

Categories of density	First observer	Second observer
Low	21.3% (75)	20.7% (73)
Intermediate	38.3% (135)	40.6% (143)
High	40.3% (142)	38.6% (136)

evaluation by Statistical Package for the Social Sciences Software Package version 21 (SPSS Inc., Chicago, Illinois, USA). The mean values were derived and the levels of significance were obtained using one-way analysis of variance. Kappa statistics and ROC were also used to determine intergroup comparisons and to derive the sensitivity and specificity and cut-off points in the intensity values;  $p < 0.005$  was considered statistically significant. This study included a total of 200 patients, of whom 96 were males and 104 were females. The mean age group of the study sample was 42.5 years. Of all the cases studied, a total of 352 implant sites were studied, which included 280 molars and 72 premolars (Table 1). The mean bone density of males was  $690.5 \pm 104.12$  HU, and in females, it was  $580.20 \pm 120.2$  HU. Overall, the mean bone density in the posterior mandible was  $628.0 \pm 20.19$  HU. Means of all the recorded values given by both the observers separately in two sittings are tabulated in Table 2. Thus, based on all the recorded observations by the two observers, overall, 21% of sites were of low bone density, 39.5% were of intermediate density, and 39.4% were of high density. Concurrently, other implant angulation measures were also done (Fig. 4). The ROC analysis presented that the CBCT intensity values had a high predictive power for predicting both high-density and intermediate-density sites ( $p < 0.005$ ).

## DISCUSSION

As already discussed by various authors, we know that for the successful placement of implants, assessment of the bone density of that area is very important and that it plays an important role in the success of the osseointegration of the implants.<sup>5,6</sup> Martinez et al reported, in their study, that in poor bone density, the primary implant stability is lower than on implants placed in denser

**Fig. 4:** Qualitative evaluation of available bone in posterior mandible on CBCT

bone.<sup>7</sup> Recently, the use of CBCT in dentistry has been significantly increased. This is mainly due to the benefits of CBCT, such as patient comfort, lower radiation doses, and lower cost in comparison to the conventional CT. In a study conducted by Nackaerts et al, it was reported that the conventional CT showed stable HU values, whereas CBCT results were not as reliable. They justified themselves saying that CBCT values are influenced by various other additional factors, such as the kind of device used, imaging parameters, and its positioning.<sup>8</sup> Thus, in the present study, we assessed the preoperative bone density of mandibular posterior region for implant placement using CT-derived bone densities in HU. The sample size for the present study was a total of 200 patients with a mean age of 42.5 years. In these patients, a total of 352 (72 for premolar areas and 280 for molar areas) implant sites were studied. When we reviewed the literature, we came across several classifications that have been proposed for subjective bone density assessment.<sup>9,10</sup> Lekholm and Zarb,<sup>9</sup> in their classification, graded bone density as: Q1 in which almost the entire jaw has homogenous compact bone, Q2 in which a thick layer of compact bone surrounds a core of dense trabecular bone, Q3 had a thin layer of cortical bone surrounding a dense trabecular bone, and Q4 had a thin layer of cortical bone surrounding a low-density trabecular bone. Later, Rebaudi et al<sup>5</sup> classified the subjective bone density into hard, normal, and soft, and suggested this classification to be used in combination with objective bone density analysis. Some more studies done previously by de Oliveira et al,<sup>11</sup> Norton and Gamble,<sup>12</sup> and Trisi and Rao<sup>13</sup> showed difficulty in the subjective classification of the bone density. Thus, similar to Rebaudi classification, Alkhader et al<sup>14</sup> proposed to classify bone density at implant site into low, intermediate, and high density. In the present study, we also used a similar classification to classify the bone



density at the implant site by two different experienced observers.

Gender difference was not significant in the studied sample, but still it was observed that the mean bone density of males was  $690.5 \pm 104.12$  HU and that in females, it was  $580.20 \pm 120.2$  HU. Thus, our results showed that the mean bone density in males was significantly higher than in females. The results of our study were in accordance with the study of Turkeyilmaz et al<sup>15</sup> who also reported similar results. Overall, from this study, it was seen that the mean bone density of the posterior mandible was  $628.0 \pm 20.19$  in the mandible. Further, in the study, when we evaluated bone density by two separate observers at posterior mandibular implant sites, it was seen that both intermediate density and high density of bone were commonly found, while low-density type of bone was found to be least in this area. Contrary to this, Alkhader et al<sup>14</sup> reported that almost half of the posterior mandible sites had intermediate density, while the rest had both low- and high-density types of bone. However, both these studies emphasize the importance of site-specific evaluation of bone density before placement of implants. The results of the ROC analysis also presented that the CBCT intensity values had a high predictive power for predicting both high-density sites and intermediate-density sites ( $p < 0.005$ ). This suggests that the preoperative estimation of density values by CBCT is a reliable tool as compared with the objectively derived bone density.<sup>16,17</sup> Although this study of ours is among very few such studies, it has some limitations. First, the sample size could be increased to validate our results better. Second, the methodology and instruments used by us in the study cannot be similar for everyone. Factors, such as the shape and size of region of interest and the section of CBCT image being used for evaluation may vary and result in difference in results from other studies. Thus, all these above-mentioned factors may result in variation in the readings and results of different studies, and these results cannot be generalized. The clinical significance of our study lies in that, as we know in the present time, implants are the most predictable treatment option among both patients and the dentists, and thus, the success of treatment is very important to deliver the best results. It has been proved that bone density and implant stability are dependent on each other and osseointegration is important for the success of treatment. With advancements in dentistry and introduction of CBCT, treatment planning and prediction of appropriate implant sites could be made easy and more predictable. Thus, we can say that CBCT can be considered an alternative diagnostic tool for the bone density evaluation during treatment planning for implant placement.

## CONCLUSION

Implant-retained dental rehabilitation of missing teeth using CBCT can be considered a preferential diagnostic tool for the bone density evaluation during treatment planning for implant placement. The CBCT images provide 3D outlooks of jawbone both qualitatively and quantitatively. Therefore, for predicting the bone densities in posterior mandible for determining implant sites, CBCT values could be reliably used. Authors also recommend some future long-term studies with higher number of subjects so as to explore the age change occurring in the bone that can affect the treatment longevity and outcomes.

## CLINICAL SIGNIFICANCE

The maximum thickness of cortical bone is usually seen in posterior mandible, and therefore, it is very crucial to explore the right bone density in this area of maximum masticatory load. The study results of our assessments clearly indicate that bone density and implant stability are solely dependent on each other, wherein osseointegration is imperative for the success of treatment. However, advancements in the dental imaging science and introduction of CBCT have made the treatment planning quite easy with accurate prediction of future treatment outcomes.

## REFERENCES

1. Swami V, Vijayaraghavan V, Swami V. Current trends to measure implant stability. *J Indian Prosthodont Soc* 2016 Apr-Jun;16(2):124-130.
2. Hiasa K, Abe Y, Okazaki Y, Nogami K, Mizumachi W, Akagawa Y. Preoperative computed tomography-derived bone densities in Hounsfield units at implant sites acquired primary stability. *ISRN Dent* 2011;2011:678729.
3. Farré-Pagés N, Augé-Castro ML, Alaejos-Algarra F, Mareque-Bueno J, Ferrés-Padró E, Hernández-Alfaro F. Relation between bone density and primary implant stability. *Med Oral Patol Oral Cir Bucal* 2011 Jan;16(1):e62-e67.
4. Scarfe WC, Farman AG, Sukovic P. Clinical applications of cone-beam computed tomography in dental practice. *J Canadian Dent Assoc* 2006 Feb;72(1):75-80.
5. Rebaudi A, Trisi P, Cella R, Cecchini G. Preoperative evaluation of bone quality and bone density using a novel CT/micro CT-based hard-normal-soft classification system. *Int J Oral Maxillofac Implants* 2010 Jan-Feb;25(1):75-85.
6. Molly L. Bone density and primary stability in implant therapy. *Clin Oral Implants Res* 2006 Oct;17 (Suppl 2):124-35.
7. Martinez H, Davarpanah M, Missika P, Celletti R, Lazzara R. Optimal implant stabilization in low density bone. *Clin Oral Implants Res* 2001 Oct;12(5):423-432.
8. Nackaerts O, Maes F, Yan H, Couto Souza P, Pauwels R, Jacobs R. Analysis of intensity variability in multislice and cone beam computed tomography. *Clin Oral Implants Res* 2011 Aug;22(8):873-879.

9. Lekholm U, Zarb GA. Patient selection and preparation. In: Branemark P, editor. *Tissue-integrated prostheses. Osseointegration in clinical dentistry*. 1st ed. Chicago: Quintessence; 1985. pp. 199-209.
10. Misch CE. Density of bone: effect on treatment plans, surgical approach, healing, and progressive bone loading. *Int J Oral Implantol* 1990;6(2):23-31.
11. de Oliveira RC, Leles CR, Normanha LM, Lindh C, Ribeiro-Rotta RF. Assessments of trabecular bone density at implant sites on CT images. *Oral Surg Oral Med Oral Pathol Oral Radiol Endod* 2008 Feb;105(2):231-238.
12. Norton MR, Gamble C. Bone classification: an objective scale of bone density using the computerized tomography scan. *Clin Oral Implants Res* 2001 Feb;12(1):79-84.
13. Trisi P, Rao W. Bone classification: clinical-histomorphometric comparison. *Clin Oral Implants Res* 1999 Feb;10(1):1-7.
14. Alkhader M, Hudieb M, Khader Y. Predictability of bone density at posterior mandibular implant sites using cone-beam computed tomography intensity values. *Eur J Dent* 2017;11:311-316.
15. Turkyilmaz I, Tözüm TF, Tumer C, Ozbek EN. Assessment of correlation between computerized tomography values of the bone, and maximum torque and resonance frequency values at dental implant placement. *J Oral Rehabil* 2006 Dec;33(12):881-888.
16. Shapurian T, Damoulis PD, Reiser GM, Griffin TJ, Rand WM. Quantitative evaluation of bone density using the Hounsfield index. *Int J Oral Maxillofac Implants* 2006 Mar-Apr;21(2):290-297.
17. Fuh LJ, Huang HL, Chen CS, Fu KL, Shen YW, Tu MG, Shen WC, Hsu JT. Variations in bone density at dental implant sites in different regions of the jawbone. *J Oral Rehabil* 2010 May;37(5):346-351.